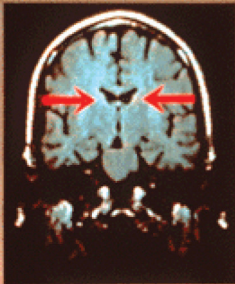


FIGURE 13.12 Magnetic Resonance Imaging Showing Differences in Brain Ventricle Size in Twins—One With Schizophrenia, One Not

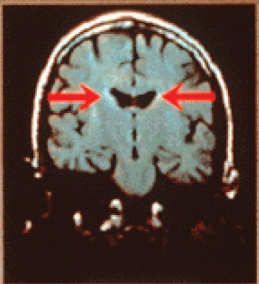
Source: Image courtesy of NIH, Dr. Daniel Weinberger, Clinical Brain Disorders Branch.

SCHIZOPHRENIA IN MONOZYGOTIC TWINS

Pair no. 2: 44 year old males



UNAFFECTED



AFFECTED